

- stenosis in a pregnant woman. *Nephrol Dial Transplant* 1998;13:2920–3.
5. Lyons CW, Colmorgen GH. Medical management of pheochromocytoma in pregnancy. *Obstet Gynecol* 1988;72:450–1.
 6. Sam S, Molitch ME. Timing and special concerns regarding endocrine surgery during pregnancy. *Endocrinol Metab Clin North Am* 2003;32:337–54.
 7. Bravo EL. Evolving concepts in the pathophysiology, diagnosis, and treatment of pheochromocytoma. *Endocr Rev* 1994;15:356–68.

8. Harper MA, Murnaghan GA, Kennedy L, Hadden DR, Atkinson AB. Pheochromocytoma in pregnancy: five cases and a review of the literature. *Br J Obstet Gynaecol.* 1989; 96:594–606.
9. Burgess GE 3rd. Alpha blockade and surgical intervention of pheochromocytoma in pregnancy. *Obstet Gynecol* 1979; 53:266–70.

Received March 23, 2004. Received in revised form April 30, 2004. Accepted May 7, 2004.

Mucous Membrane Pemphigoid of the Vulva

Andrew T. Goldstein, MD,
Grant J. Anhalt, MD, Daisy Klingman, MD,
and Lara J. Burrows, MD

Division of Gynecologic Specialties and Department of Dermatology, The Johns Hopkins School of Medicine, Baltimore, Maryland; New York University School of Medicine, New York, New York; and Magee-Womens Hospital, the University of Pittsburgh School of Medicine, Pittsburgh, Pennsylvania

BACKGROUND: Mucous membrane pemphigoid is a rare autoimmune blistering disease primarily affecting mucosal surfaces. Blistering and scarring may occur in the eyes, mouth, esophagus, larynx, and on the vulva. Scarring can result in severe structural changes to the vulva that may mimic the findings of other inflammatory dermatologic disorders of the vulva, including lichen sclerosus and lichen planus.

CASE: A 58-year-old woman presented with vulvar erosions, esophagitis, and laryngeal blisters. The clinical picture and the histopathology of a vulvar biopsy were suggestive of erosive lichen planus. Direct immunofluorescence, however, revealed findings diagnostic of mucous membrane pemphigoid.

CONCLUSION: This case illustrates the importance of examining extragenital mucosal surfaces of any woman presenting with vulvar lesions. In addition, it demonstrates the importance of vulvar biopsy and the usefulness of direct immunofluorescence to differentiate between conditions with similar clinical and histopathologic changes. (*Obstet Gynecol* 2005;105:1188–90. © 2005 by The American College of Obstetricians and Gynecologists.)

Mucous membrane pemphigoid is a group of rare autoimmune blistering diseases that primarily affects muco-

sal surfaces. Blisters are subepidermal and may heal with severe scarring. Direct immunofluorescence reveals linear deposits of immunoglobulin G (IgG) and/or C3 at the basement membrane of involved areas.¹ Common sites for blistering include the mouth and eyes;² less common sites for mucosal blistering include the nasal epithelium, esophagus, larynx, and vulva. Cutaneous blistering and scarring often occurs. Long-term effects include adhesions between the palpebral and bulbar conjunctiva (symblepharon) and the formation of synechiae between adjacent mucosal surfaces.³ Scarring may ultimately lead to blindness, stridor, dysphagia, and dyspareunia.²

Mucous membrane pemphigoid can present as a vulvar disease. Blistering and subsequent scarring can result in severe structural changes to the vulva, including agglutination or resorption of the labia minora, stenosis of the introitus, stenosis of the urethral meatus, and phimosis of the clitoris.³ The gross appearance of vulvar mucous membrane pemphigoid may mimic the findings of other more common inflammatory dermatologic disorders of the vulva, including lichen sclerosus and erosive lichen planus. This similarity can present a diagnostic dilemma and can have significant clinical implications.^{3,4}

CASE

A 58-year-old woman presented to a referral center for vulvovaginal disease with an 8-month history of vulvar erosions and pain. For the preceding 9 months, she had been treated by a gastroenterologist for severe erosive esophagitis, by an otolaryngologist for blistering of her laryngeal mucosa, and by a periodontist for erosions and blisters on her buccal mucosa. She has been treated with fluconazole, valacyclovir, and hydrocortisone for her vulvar symptoms, none of which palliated these symptoms.

Examination of the vulva and vagina revealed poorly demarcated erosions in the vestibule and fissuring of the perineum (Fig. 1). The vaginal mucosa was erythematous and friable. A copious yellowish vaginal discharge was found to be composed predominately of leukocytes

Address reprint requests to: Andrew T. Goldstein, MD, 2002 Medical Parkway, Suite 215 Annapolis, Maryland, 21401; e-mail: obstetrics@yahoo.com.



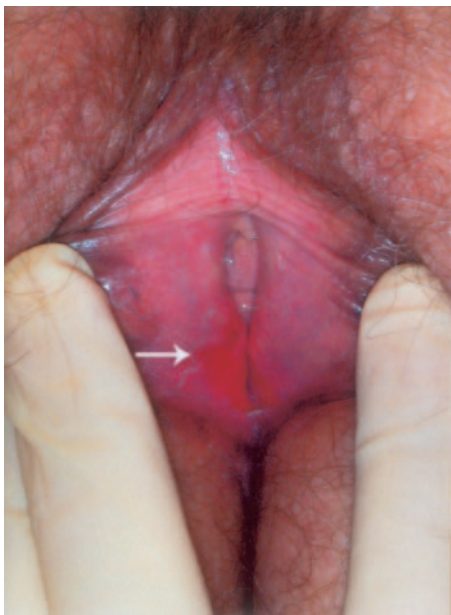


Fig. 1. Erosion in the vulvar vestibule.
Goldstein. *Mucous Membrane Pemphigoid*. *Obstet Gynecol* 2005.

and parabasal cells. Vaginal culture revealed a predominance of *Lactobacillus* species.

A biopsy of the vulvar vestibule was evaluated by a dermatopathologist. The histopathologic changes revealed lichenoid inflammation consistent with erosive lichen planus. Because of the history of extensive blistering of the gingival and laryngeal mucosa, a biopsy was sent for direct immunofluorescence microscopy, which revealed heavy linear deposition of IgG and C3 on the basement membrane (Fig. 2). These findings are diagnostic for mucous membrane pemphigoid.

The patient was treated with prednisone (40 mg/d) and mycophenolate mofetil (CellCept, Roche, Nutley, NJ), an antimetabolite immunosuppressant with a selective antiproliferative effect on T and B lymphocytes.⁵ In addition, she was treated with topical clobetasol combined with mechanical dilation of the vagina to maintain vaginal patency. Within 8 weeks, she had resolution of her vulvar erosions, gingival lesions, and dyspepsia.

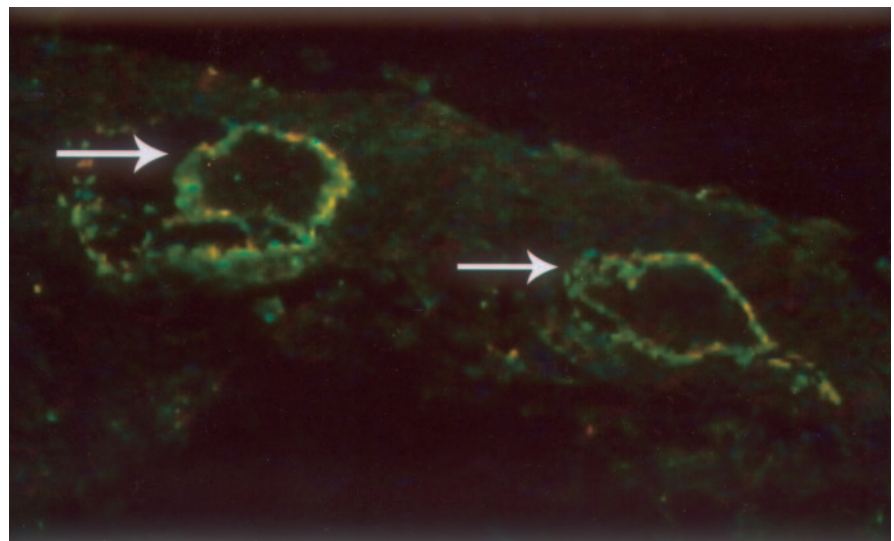
COMMENT

Differentiating between the various dermatologic disorders of the vulva is often difficult because any chronic inflammation can cause vulvar scarring and loss of vulvar architecture. Lichen sclerosus, erosive lichen planus, pemphigus vulgaris, and mucous membrane pemphigoid can have very similar clinical presentations. Although all of these disorders may respond to topical superpotent corticosteroids,⁴ this does not obviate the need for a correct diagnosis because these diseases may affect different organ systems and have different prognoses.^{3,4,6}

In 1999, the First International Conference on Mucous Membrane Pemphigoid established the diagnostic criteria for mucous membrane pemphigoid: blisters on mucous membranes, which must be examined by direct immunofluorescence microscopy to demonstrate continuous deposits of any one or a combination of IgG, IgA, or C3 along the basement membrane zone.¹ Although the histopathologic changes of a biopsy and indirect immunofluorescence of a patient's serum can be useful to help make the diagnosis of mucous membrane pemphigoid, results of these tests can be nonspecific and, therefore, are not part of the diagnostic criteria for mucous membrane pemphigoid.¹ This point is illustrated by our

Fig. 2. Direct immunofluorescence showing deposition of C3 along the basement membrane zone.

Goldstein. *Mucous Membrane Pemphigoid*.
Obstet Gynecol 2005.



patient, in whom the histopathologic changes of mucous membrane pemphigoid were mistaken for erosive lichen planus. Differentiating between these 2 diseases is important because ocular, laryngeal, and esophageal involvement are much more common in mucous membrane pemphigoid.⁷ Early and aggressive treatment of mucous membrane pemphigoid with immunosuppressants is often necessary to prevent blindness. Therefore, we suggest that a biopsy for direct immunofluorescence microscopy should be performed on all erosive, ulcerative, or bullous vulvar lesions.

There have been several case reports in which the diagnosis of mucous membrane pemphigoid was confused with lichen sclerosus.^{3,4} Differentiating between these 2 entities is important because 3–5% of women with vulvar lichen sclerosus will develop carcinoma,⁸ whereas vulvar carcinoma associated with mucous membrane pemphigoid has not been reported.

The same consensus conference also established treatment guidelines for mucous membrane pemphigoid. Any patient who has vulvar involvement should initially be treated with prednisone and either cyclophosphamide or azathioprine.¹ More recently, however, there have been case reports describing the successful treatment of mucous membrane pemphigoid with a combination of steroids and mycophenolate mofetil, a nonsteroidal immunosuppressive drug approved by the U.S. Food and Drug Administration to prevent rejection after allograft transplantation.⁵ Mycophenolate mofetil blocks de novo purine synthesis, thereby inhibiting T and B lymphocytes, which are highly dependent on guanosine nucleotides for proliferation and antibody production. Mycophenolate mofetil is usually very well tolerated, without significant myelosuppression, hepatotoxicity, or nephrotoxicity.⁵

This case illustrates the importance of examining extragenital mucosal surfaces of any woman presenting with vulvar lesions and scarring. In addition, it demon-

strates the importance of vulvar biopsy and the usefulness of direct immunofluorescence to differentiate between conditions with similar clinical and histopathologic changes.

REFERENCES

1. Chan LS, Ahmed AR, Anhalt GJ, Bernauer W, Cooper KD, Elder MJ, et al. The first international consensus on mucous membrane pemphigoid: definition, diagnostic criteria, pathogenic factors, medical treatment, and prognostic indicators. *Arch Dermatol* 2002;138:370–9.
2. Frith P, Charnock M, Wojnarowska F. Cicatricial pemphigoid diagnosed from ocular features in recurrent severe vulval scarring. Two case reports. *Br J Obstet Gynaecol* 1991;98:482–4.
3. Edwards L, Hays S. Vulvar cicatricial pemphigoid as a lichen sclerosus imitator. A case report. *J Reprod Med* 1992;37:561–4.
4. Marren P, Walkden V, Mallon E, Wojnarowska F. Vulvar cicatricial pemphigoid may mimic lichen sclerosus. *Br J Dermatol* 1996;134:522–4.
5. Megahed M, Schmiedeberg S, Becker J, Ruzicka T. Treatment of cicatricial pemphigoid with mycophenolate mofetil as a steroid-sparing agent. *J Am Acad Dermatol* 2001;45:256–9.
6. Farrell AM, Kirtschig G, Dalziel KL, Allen J, Dootson G, Edwards S, et al. Childhood vulval pemphigoid: a clinical and immunopathological study of five patients. *Br J Dermatol* 1999;140:308–12.
7. Boedeker CC, Termeer CC, Staats R, Ridder GJ. Cicatricial pemphigoid in the upper aerodigestive tract: diagnosis and management in severe laryngeal stenosis. *Ann Otol Rhinol Laryngol* 2003;112:271–5.
8. Carli P, De Magnis A, Mannone F, Botti E, Taddei G, Cattaneo A. Vulvar carcinoma associated with lichen sclerosus: experience at the Florence, Italy, Vulvar Clinic. *J Reprod Med* 2003;48:313–8.

Received April 8, 2004. Received in revised form May 4, 2004. Accepted May 12, 2004.

